



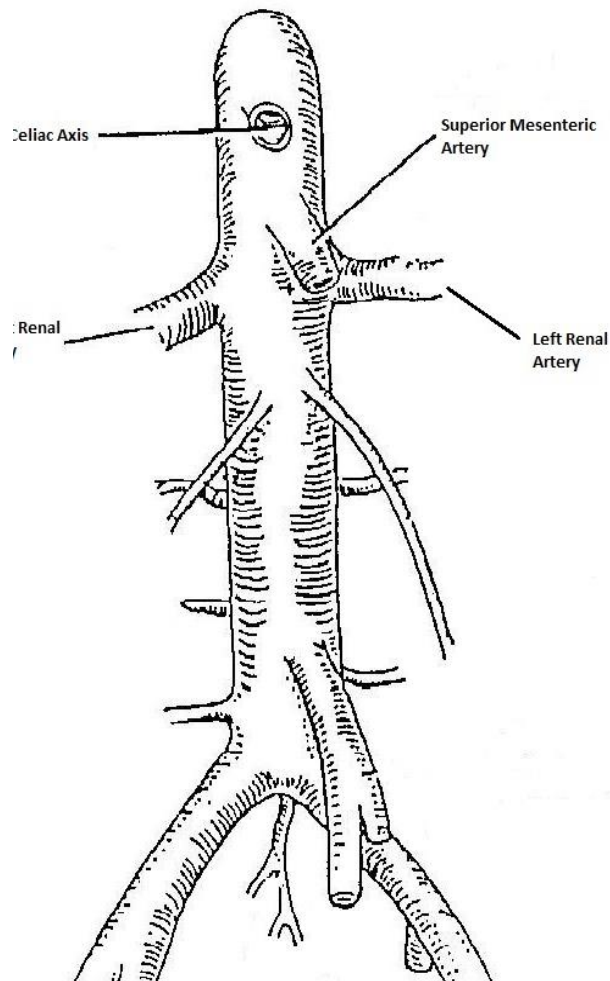
CARDIORISK AAA SCREENING

Patient Name: Kipp, Andy Date: 8/4/2021

DOB: 7/27/1959 Sex: M

Referring Provider: Zachary Young, DO

Vascular Technician: Dana Johannesson



Aorta Prox

1.2 cm Trans X 1.2 cm AP

Aorta Mid

2.5 cm Trans X 1.8 cm AP

Aorta Distal

2.3 cm Trans X 2.5 cm AP

Comments: No Abdominal Aortic Aneurysm was identified in the submitted images. Limited visibility of the Abdominal Aorta due to overlying bowel gas. Unable to exclude the possibility of an Abdominal Aortic Aneurysm in the unvisualized portion(s) of the Abdominal Aorta. No plaque identified in the submitted images. Further evaluation should be considered if clinically indicated.



